

Surgical Indications and Results for Non-functioning Pituitary Adenomas

a report by

Marco Losa,¹ Elena Peretti² and Pietro Mortini³

1. Assistant Professor; 2. Research Fellow; 3. Professor of Neurosurgery, Department of Neurosurgery, San Raffaele Scientific Institute, University Vita-Salute

DOI:10.17925/EE.2008.04.02.86

Non-functioning pituitary adenomas (NFPAs) are benign tumours that do not produce any biologically active hormones and constitute 16–20% of all pituitary adenomas.¹ NFPAs have a similar clinical presentation, but represent a heterogeneous group of tumours. Recent advances in immuno-cytochemical and molecular biological techniques showed that more than 80% of clinical NFPAs, previously called chromophobe adenomas, contain follicle-stimulating hormone (FSH), lutenising hormone (LH), the common alpha-subunit, FSH beta-subunit or LH beta-subunit.^{2,3} NFPAs may, rarely, stain positive for adrenocorticotrophic hormone (ACTH), prolactin (PRL), thyroid-stimulating hormone (TSH) or growth hormone (GH) without any clinical or biochemical evidence of hormone hypersecretion.^{4,5}

NFPAs are usually asymptomatic until they become large enough to cause mass effects. Diagnosis is frequently made when they are at the macro-adenoma stage. Visual deficit is the most frequent symptom that leads a patient to discover a pituitary mass. Patients often show bi-temporal haemianopsia secondary to compression of the optic chiasm by suprasellar extension of the tumour. If the lesion invades the cavernous sinus, it can also compromise oculomotor nerves, causing diplopia, ptosis and ophthalmoplaegia. Another common symptom is

headache, which is present in 20–50% of cases.^{6–9} Patients may report hormonal abnormalities, most commonly hypogonadism (decreased libido, impotence or menstrual dysfunction in pre-menopausal women), which may be secondary to hyperprolactinaemia. Other pituitary deficiencies may be present in more than 30% of patients with macro-adenomas.⁹

An uncommon presentation of NFPAs is tumour apoplexy due to sudden bleeding within the adenomatous tissue. Patients develop a sudden and excruciating headache, often accompanied by nausea and vomiting. Within hours, neurological deficits, secondary to compression of the optic pathway or oculomotor nerves, ensue. While most cases of pituitary apoplexy are spontaneous, precipitating factors may include head injury, anticoagulant therapy, radiation therapy or dynamic endocrine tests.¹⁰

Pituitary Incidentalomas – Indications for Treatment

An increasing proportion of NFPAs are currently recognised by chance when brain imaging (magnetic resonance imaging [MRI] or computed tomography [CT]) is performed for unrelated reasons (the so-called ‘pituitary incidentalomas’).^{1,11} While there is a current consensus that NFPAs that are causing symptoms should be treated to allow decompression of the normal pituitary gland and the optic pathway, there is debate as to whether pituitary incidentalomas require treatment when first detected.

NFPAs that present as incidentalomas can occur as either micro- or macro-adenomas. This distinction is important, as there are practical differences in the management of these two tumours.¹¹ Incidental micro-adenomas do not cause symptoms related to mass effect and, once hormonal hypersecretion has been excluded, they should be managed conservatively.^{1,12} Observation with close imaging monitoring of tumour size is recommended with MRI and basal hormone testing at six and 12 months.¹³ If tumour size remains stable and the pituitary function is not compromised, the patient can be followed up less frequently (e.g. every two years).¹¹ Growth of micro-adenomas is usually slow. Prospective studies on the natural history of these tumours demonstrated that significant growth over time was relatively uncommon.^{1,12,14} In a Japanese survey, fewer than 10% of micro-adenomas increased in size during a median follow-up of 45 months.¹⁵ Whenever significant changes in tumour size or alteration of pituitary function are detected, surgery is advised to prevent hypopituitarism or visual deficit.¹²

When incidentalomas are discovered at a later stage (i.e. when they are macro-adenomas), there is much controversy about the indications for treatment. At this stage of development, the natural



Marco Losa is a Senior Assistant Professor in the Department of Neurosurgery at the San Raffaele Scientific Institute in Milan, where he is also Head of the Pituitary Unit. His primary clinical research interest is the diagnosis and therapy of pituitary diseases and, particularly, of pituitary adenomas. Dr Losa has written numerous articles published in peer-reviewed medical journals and has collaborations with basic-research teams for the study of pathophysiological aspects of pituitary tumours.

E: losa.marco@hsr.it



Elena Peretti is a Research Fellow in Endocrinology and Metabolism at the San Raffaele Scientific Institute in Milan. Her research interests include neurological sequelae of diabetes and neuroendocrinology. She has experience in the clinical care of patients with diabetes and various endocrinopathies. Dr Peretti is participating as a study investigator in pharmacological trials for the treatment of diabetic neuropathy and glycaemic control in patients with diabetes.



Pietro Mortini is a Professor of Neurosurgery and Chairman of the Department of Neurosurgery at the University Vita-Salute San Raffaele in Milan. He has performed more than 2,500 surgical procedures at this institution, mainly for pituitary adenomas, other skull base tumours, brain tumours and cerebrovascular disorders. Professor Mortini is the author or co-author of numerous articles published in international peer-reviewed medical journals.

history of the lesion is characterised by a trend for slow growth.¹⁴ Several factors must be taken into account when deciding which patients should be referred for therapy and which to closely monitor. Large tumours and a young age should favour the decision to treat the patient, while co-existent co-morbidity may suggest a more conservative approach.

Surgical Treatment

The first-choice treatment for NFPAs is surgery and should be performed by a surgeon experienced in pituitary surgery. The goals of surgical treatment are to remove as much tumour as possible, relieve compression on adjacent nervous structures and obtain a definitive pathological diagnosis. Usually a trans-sphenoidal approach is used. With tumours that have a prevalent extension well beyond the boundaries of the sella, a transcranial surgical approach is indicated.¹⁶ Disadvantages of the transcranial approach include the risk of mortality, due to damage to vital structures, major morbidity (risk of seizures, worsening of vision, increased duration of hospitalisation), hypopituitarism and diabetes insipidus. The trans-sphenoidal technique, via sub-labial or intranasal incision, is preferred in the vast majority of patients (>95%).

The natural course of NFPAs is largely unknown; if the tumour is large, the risk of further expansion is expected to be high, since the tumour has a proven propensity to grow. At present, only a few studies have assessed the natural course of untreated NFPAs, mainly because the majority of patients with macro-adenomas are operated on. Some recent studies have suggested a higher propensity for growth than previously thought. Karavitaki et al.¹⁷ studied 24 patients who had NFPAs and found that the 48-month probability of enlargement was 44%. Of this group, 57% showed new or worsening visual-field defects and an additional 21% showed chiasmatic compression on

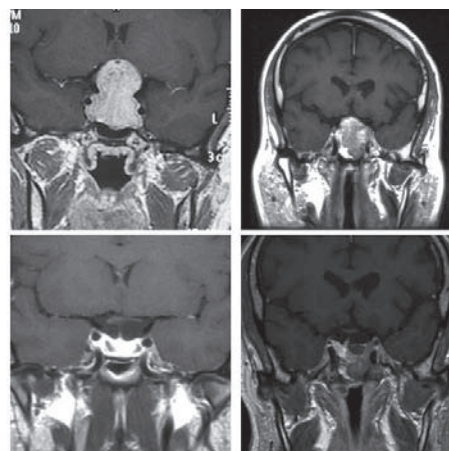
The goals of surgical treatment are to remove as much tumour as possible, relieve compression on adjacent nervous structures and obtain a definitive pathological diagnosis.

imaging, without vision deterioration. Arita and colleagues¹⁸ found that 21 of 42 (50%) NFPAs (mean size 18.3±7mm) increased by at least 10% over an average of 32 months after the initial evaluation. Ten patients became symptomatic over a mean of about five years, with four of these 10 (9.5% of the entire cohort) suffering symptomatic pituitary apoplexy.

Early Results of Surgery

Peri-operative mortality is usually minimal – fewer than 1% of cases – when performed by an experienced surgeon.^{9,19} The most frequent early complication of surgery is diabetes insipidus, which is usually transient. Other complications include cerebrospinal leakage (seldom requiring surgical repair), transient hyponatraemia, visual worsening or transient cranial nerve palsy and sellar haematoma.⁹

Figure 1: Coronal Pre-operative (top) and Post-operative (bottom) Gadolinium-enhanced, T₁-weighted Magnetic Resonance Images of Two Patients Undergoing Surgery Because of Non-functioning Pituitary Adenomas



In the first patient (left lower panel), no apparent residual tumour is visible three months after surgery. Further imaging follow-up showed no tumour recurrence 30 months after surgery. In the second patient (right lower panel), there is evidence of a tumour near the left cavernous sinus. This patient underwent gamma-knife radio-surgery three months afterwards. At the last follow-up, one year after gamma knife surgery, the tumour was unchanged.

Resolution of clinical symptoms has been reported in various surgical series. Trans-sphenoidal surgery allows improvement of visual disturbances in approximately 80% of all patients.^{16,20} Visual recovery may be demonstrated a few days after surgery.^{21–23} In a recent study by Losa and co-workers, visual function normalised in 110 (39.4%) and improved in 141 (50.6%) of the 279 patients with pre-operative impairment of visual function.⁹ Resolution of oculomotor nerve palsy occurred in 18 of the 22 patients (81.8%) with diplopia at presentation.⁹ Surgery provides immediate relief of headache in the majority of patients complaining of this symptom at diagnosis.^{16,24,25}

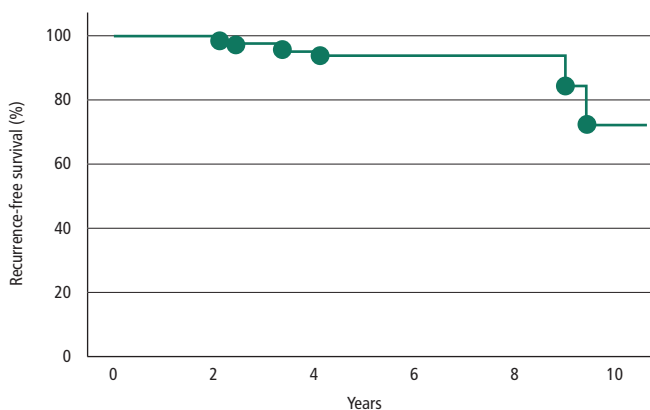
Surgical treatment improves neurological alterations in the majority of patients with NFPAs. Recovery of impaired pituitary function is, in contrast, less likely. In the literature there is large variability in the results concerning pituitary function after surgery. In a recent review by Dekkers et al.,²⁶ some studies showed, to a variable degree, an improvement after surgery,^{6,23,27–29} whereas others could not demonstrate significant improvement in pituitary function^{7,30} or even reported worsening of pituitary function.^{19,31,32} It is likely that some of the variability in the results might be explained by the different criteria used to define hypopituitarism, the use of post-operative radiation therapy and differences of patient baseline characteristics.¹⁶ Dekkers reported that hypopituitarism is still present in a considerable proportion of patients after surgery (GH deficiency in about 83%, gonadotropin deficiency in about 60% and TSH and ACTH deficiency in about 30%).²⁶ In our series of 482 patients, post-operative worsening of gonadal, thyroid or adrenal function occurred in 5.8, 5.6 and 7.5% of patients with normal gonadal, thyroid or adrenal function before surgery, respectively.⁹ Recovery of normal gonadal, thyroid or adrenal function occurred in 32.8, 35.7 and 41.6% of the patients with impaired gonadal, thyroid or adrenal function before surgery, respectively.⁹ As a whole, 49.0, 20.3 and 19.6% of the patients had impaired gonadal, thyroid and adrenal function after surgery, respectively.⁹

Table 1: Frequency of Residual Tumour Visible on the First Post-operative Neuro-imaging in Patients Operated on Because of a Non-functioning Pituitary Adenoma in Recently Published Surgical Series

Authors	Year	Number of Patients	Number with Residual Post-op. Tumour (%)	Type of Imaging
Zhang et al. ³⁶	1999	208	62 (29.8%)	CT-MRI
Woolfons et al. ³³	2000	72	52 (72.2%)	CT-MRI
Greenman et al. ³⁵	2003	122	92 (75.4%)	MRI
Nomikos et al. ²⁹	2004	721	278 (38.6%)	CT-MRI
Dekkers et al. ¹⁹	2006	109	80 (73.0%)	MRI
Ferrante et al. ⁸	2006	290	185 (64.5%)	CT-MRI
Losa et al. ⁹	2008	475	173 (36.4%)	MRI

CT = computed tomography; MRI = magnetic resonance imaging.

Figure 2: Kaplan-Meier Analysis of Time to Recurrence of Non-functioning Pituitary Adenoma in 135 Patients Who Had Residual or Recurring Tumour Treated with Gamma Knife Radio-surgery



Six patients had relapse during follow-up. In all six cases, there was growth of adenomatous tissue located in the contralateral side of the treated lesion. The recurrence-free survival at five years was 94.1% (95% confidence interval 88.3–99.9%).

Improvement of clinical symptoms by no means indicates total removal of the tumour.¹⁶ Due to the lack of a reliable tumour markers, the best method to assess the degree of surgical de-bulking is to obtain an imaging study (MRI is preferable to CT) three to six months after surgery (see Figure 1). As most NFPAs are large and invasive at diagnosis, persistence of residual tumour after surgery is relatively frequent (see Table 1). In an Italian database of NFPAs, surgery represented the first therapeutic approach (98% of patients) and radiological cure, defined as the absence of tumour remnants on post-operative neuro-imaging, was achieved in 35.5% of patients.⁸ This result is in agreement with previous studies.^{33–35} In centres that are highly specialised in pituitary surgery and perform high volumes of surgical procedures each year, the reported percentage of apparent total tumour removal approaches 60–70% of patients with NFPAs.^{9,29,36} The variables that are associated with an unfavourable early surgical result are the presence of tumour invasion into the cavernous sinus,^{9,35} greater maximum tumour diameter^{9,29} and, in our experience, absence of tumour apoplexy.⁹

Tumour Recurrence and Treatment After Surgery

Clinical recurrence of NFPAs is defined by the occurrence of symptoms secondary to compression of the surrounding structures. By this definition, it is clear that clinical recurrence can be caused only when the tumour is very large, necessitating another surgical procedure to improve the clinical picture. In old surgical series, such recurrences were reported in more than

50% at five years.^{37,38} A goal of therapy should be to avoid repeat surgery, if not strictly necessary. A more precise definition of tumour recurrence is based on imaging criteria, which needs to be performed routinely in patients operated on for NFPAs. Recurrence of the pituitary tumour is defined by the appearance on repeated MRI of pathological tissue not detected at an earlier examination or by further growth of adenomatous tissue that was always detected on previous MRIs.

Recurrence of NFPAs after surgery is reported in between 12 and 45% of cases.^{7,16,24,33,39–41} This variability reflects different surgical expertise, different criteria to define recurrence, the length of follow-up and the use of adjuvant radiotherapy.¹⁶ In some studies the completeness of tumour removal was not objectively ascertained. Recurrence after apparent complete tumour removal seems to be uncommon. In a small series,⁴² only two of 32 patients (6.2%) with apparent gross total tumour removal and no post-operative radiotherapy had radiological recurrence of NFPAs after a mean follow-up of more than five years. Other studies also found a similarly low rate of tumour recurrence when the first post-operative MRI showed no residual tumour.^{19,32,33,35} In our large series, the five-year recurrence-free survival of such patients was 87.1%.⁹ The use of prophylactic radiation therapy may not be warranted, provided that patients are willing to continue a tight follow-up with appropriate imaging studies.

The risk of tumour re-growth in patients who have had an incomplete removal of a NFPA is more controversial. Most series^{8,9,33,35,41} report a high risk of re-growth when the tumour residue is left untreated. In our series, the five-year recurrence-free survival was only 39.2% and the risk does not seem to plateau even after this interval.⁹ In a study by Greenman and co-workers,³⁵ factors associated with a higher risk of tumour growth were tumour size and invasion before surgery and the size of the tumour residue after surgery. In contrast, our multivariate analysis failed to identify prognostic factors for the risk of tumour growth.⁹

In a study by Greenman and co-workers, factors associated with a higher risk of tumour growth were tumour size and invasion before surgery and the size of the tumour residue after surgery.

Although not universally accepted, radiation therapy is considered a very effective adjuvant therapy after incomplete removal of NFPAs. There are no prospective trials that compare the effects of radiation versus observation alone, but several studies suggest a higher control of local growth with radiotherapy. In one study, 15-year recurrence-free survival was 93% in one institution that routinely administered radiotherapy to all patients operated on for NFPAs, compared with 33% in another institution that simply followed patients after surgery.⁴⁰ Multivariate analysis showed that the only prognostic factor for tumour re-growth was the administration of radiotherapy. A similar conclusion was reached in our recent series.⁹ A highly significant difference in the likelihood of tumour recurrence between irradiated and non-irradiated patients with residual NFPAs after surgery has been confirmed in

several other studies.^{7,33,41,43} Similar control of local tumour growth can be achieved even with gamma-knife radio-surgery, which has the possible advantage of sparing the pituitary gland.⁴⁴ A recent update of our series of patients treated with the gamma-knife for residual NFPAs confirms our previous results (see *Figure 2*).

Other studies report diverging results. Dekkers et al. reported tumour re-growth in only 10% of patients with residual NFPAs who did not undergo radiotherapy, with a mean time to tumour re-growth of approximately six years.¹⁹

Conclusion

NFPAs are the most frequent type of pituitary tumour necessitating surgical treatment. With the exception of small asymptomatic lesions discovered incidentally, or patients of advanced age in a poor health condition, patients with NFPAs should always undergo surgical removal of the pituitary tumour by an experienced neurosurgeon. Whenever possible, the less traumatic trans-sphenoidal approach should be used. Neurological symptoms due to compression of surrounding structures are expected to show clear improvement soon after surgery. Impaired pituitary function may recover in a small percentage of patients. Total removal of the tumour

is the aim of surgery. This can be accomplished in about 50–70% of patients, but is unusual in patients with very large tumours that invade the cavernous sinus. If residual tumour is present after maximal surgical removal, the option is to irradiate the patient to diminish the likelihood of clinical recurrence of NFPA. This decision must be balanced against the

Neurological symptoms due to compression of surrounding structures are expected to show clear improvement soon after surgery. Impaired pituitary function may recover in a small percentage of patients.

possible risk of radiation. Even patients with apparent total removal of NFPAs must be monitored closely with neuroimaging to detect a possible early recurrence of the tumour so that an appropriate decision about further radiation therapy can be discussed with the patient. ■

- Chanson P, Brochier S, Non-functioning pituitary adenomas, *J Endocrinol Invest*, 2005;28(Suppl):93–9.
- Asa SL, Gerrie BM, Singer W, et al., Gonadotropin secretion in vitro by human pituitary null cell adenomas and oncocyctomas, *J Clin Endocrinol Metab*, 1986;62:1011–19.
- Jameson JL, Klibanski A, Black PM, et al., Glycoprotein hormone genes are expressed in clinically nonfunctioning pituitary adenomas, *J Clin Invest*, 1987;80:1472–8.
- Horvath E, Kovacs K, Killinger DW, et al., Silent corticotrophic adenomas of the human pituitary gland: a histologic, immunocytologic, and ultrastructural study, *Am J Pathol*, 1980;98:617–38.
- Alexander JM, Biller BM, Bikkal H, et al., Clinically non-functioning pituitary tumours are monoclonal in origin, *J Clin Invest*, 1990;86:336–40.
- Arafah BM, Reversible hypopituitarism in patients with large nonfunctioning pituitary adenomas, *J Clin Endocrinol Metab*, 1986;62:1173–9.
- Comtois R, Beauregard H, Somma M, et al., The clinical and endocrine outcome to trans-sphenoidal microsurgery of nonsecreting pituitary adenomas, *Cancer*, 1991;68:860–66.
- Ferrante E, Ferraroni M, Castrignanò T, et al., Non-functioning pituitary adenoma database: a useful resource to improve the clinical management of pituitary tumours, *Eur J Endocrinol*, 2006;155:823–9.
- Losa M, Mortini P, Barzaghi R, et al., Early results of surgery in patients with non-functioning pituitary adenoma and analysis of the risk of tumour recurrence, *J Neurosurg*, 2008;108:525–32.
- Bioussé V, Newman NJ, Oyesiku NM, Precipitating factors in pituitary apoplexy, *J Neurol Neurosurg Psychiatry*, 2001;71:542–5.
- Daly AF, Burlacu MC, Livadariu E, Beckers A, The epidemiology and management of pituitary incidentalomas, *Horm Res*, 2007;68 (5):195–8.
- Reincke M, Allolio B, Saeger W, et al., The 'incidentaloma' of the pituitary gland. Is neurosurgery required?, *JAMA*, 1990;263:2772–6.
- Chaidarun SS, Klibanski A, Gonadotropinomas, *Semin Reprod Med*, 2002;20:339–48.
- Donovan LE, Corenblum B, The natural history of the pituitary incidentaloma, *Arch Intern Med*, 1995;155:181–3.
- Sanno N, Oyama K, Tahara S, et al., A survey of pituitary incidentaloma in Japan, *Eur J Endocrinol*, 2003;149:123–7.
- Losa M, Mortini P, Barzaghi R, et al., Endocrine inactive and gonadotroph adenomas: diagnosis and management, *J Neuro-oncol*, 2001;54:167–77.
- Karavitaki N, Collison K, Halliday J, et al., What is the natural history of nonoperated nonfunctioning pituitary adenomas?, *Clin Endocrinol (Oxf)*, 2007;67:938–43.
- Arita K, Tominaga A, Sugiyama K, et al., Natural course of incidentally found nonfunctioning pituitary adenoma, with special reference to pituitary apoplexy during follow-up examination, *J Neurosurg*, 2006;104:884–91.
- Dekkers OM, Pereira AM, Roelfsema F, et al., Observation alone after transsphenoidal surgery for nonfunctioning pituitary macroadenoma, *J Clin Endocrinol Metab*, 2006;91:1796–1801.
- Dekkers OM, Hammer S, de Keizer RJ, et al., The natural course of non-functioning pituitary macro-adenomas, *Eur J Endocrinol*, 2007;156:217–24.
- Jakobsson KE, Petruson B, Lindblom B, Dynamics of visual improvement following chiasmal decompression. Quantitative pre- and postoperative observations, *Acta Ophthalmol Scand*, 2002;80:512–16.
- Kerrison JB, Lynn MJ, Baer CA, et al., Stages of improvement in visual fields after pituitary tumor resection, *Am J Ophthalmol*, 2000;130:813–20.
- Marazuela M, Astigarraga B, Vicente A, et al., Recovery of visual and endocrine function following transsphenoidal surgery of large non-functioning pituitary adenomas, *J Endocrinol Invest*, 1994;17:703–7.
- Ebersold MJ, Quast LM, Laws ER Jr, et al., Long-term results in trans-sphenoidal removal of non-functioning pituitary adenomas, *J Neurosurg*, 1986;64:713–19.
- Bevan JS, Adams CB, Burke CW, et al., Factors in the outcome of transsphenoidal surgery for prolactinoma and nonfunctioning pituitary tumour, including pre-operative bromocriptine therapy, *Clin Endocrinol (Oxf)*, 1986;26:541–56.
- Dekkers OM, Pereira AM, Romijn JA, Treatment and follow-up of clinically non-functioning pituitary macro-adenomas, *J Clin Endocrinol Metab*, 2008;93:3717–26.
- Greenman Y, Tordjman K, Kisch E, et al., Relative sparing of anterior pituitary function in patients with growth hormone-secreting macro-adenomas: comparison with non-functioning macro-adenomas, *J Clin Endocrinol Metab*, 1995;80:1577–83.
- Webb SM, Rigla M, Wagner A, et al., Recovery of hypopituitarism after neurosurgical treatment of pituitary adenomas, *J Clin Endocrinol Metab*, 1999;84:3696–3700.
- Nomikos P, Ladar C, Fahlbusch R, Buchfelder M, Impact of primary surgery on pituitary function in patients with non-functioning pituitary adenomas – a study on 721 patients, *Acta Neurochir (Wien)*, 2004;146:27–35.
- Wichers-Rother M, Hoven S, Kristof RA, et al., Non-functioning pituitary adenomas: endocrinological and clinical outcome after trans-sphenoidal and transcranial surgery, *Exp Clin Endocrinol Diabetes*, 2004;112:323–7.
- Harris PE, Afshar F, Coates P, et al., The effects of trans-sphenoidal surgery on endocrine function and visual fields in patients with functionless pituitary tumours, *Q J Med*, 1989;71:417–27.
- Alameda C, Lucas T, Pineda E, et al., Experience in management of 51 non-functioning pituitary adenomas: indications for post-operative radiotherapy, *J Endocrinol Invest*, 2005;28:18–22.
- Woolons AC, Hunn MK, Rajapakse YR, et al., Non-functioning pituitary adenomas: indications for post-operative radiotherapy, *Clin Endocrinol (Oxf)*, 2000;53:713–17.
- Drange MR, Fram NR, Herman-Bonert V, Melmed S, Pituitary tumour registry: a novel clinical resource, *J Clin Endocrinol Metab*, 2000;85:168–74.
- Greenman Y, Ouaknine G, Veshchev I, et al., Post-operative surveillance of clinically nonfunctioning pituitary macro-adenomas: markers of tumour quiescence and re-growth, *Clin Endocrinol (Oxf)*, 2003;58:763–9.
- Zhang X, Fei Z, Zhang J, et al., Management of non-functioning pituitary adenomas with suprasellar extensions by trans-sphenoidal microsurgery, *Surg Neurol*, 1999;52:380–85.
- Hayes TP, Davis RA, Raventos A, The treatment of pituitary chromophobe adenomas, *Radiology*, 1971;98:149–53.
- Sheline GE, Tyrrell B, Pituitary adenomas. In: Phillips TL, Pinstenma DA (eds), *Radiation Oncology Annual*, New York: Raven Press, 1983:1–35.
- Sassolas G, Trouillas J, Treluyer C, Perrin G, Management of non-functioning pituitary adenomas, *Acta Endocrinol (Copenh)*, 1993;129 (1):21–6.
- Gittoes NJL, Bates AS, Tse W, et al., Radiotherapy for non-functioning pituitary tumours, *Clin Endocrinol (Oxf)*, 1998;48:331–7.
- Turner HE, Stratton IM, Byrne JV, et al., Audit of selected patients with non-functioning pituitary adenomas treated without irradiation - a follow-up study, *Clin Endocrinol (Oxf)*, 1999;51:281–4.
- Lillehei KO, Kirschman DL, Kleinschmidt-DeMasters BK, Ridgway EC, Re-assessment of the role of radiation therapy in the treatment of endocrine-inactive pituitary macro-adenomas, *Neurosurgery*, 1998;43:432–9.
- Breen P, Flickinger JC, Kondziolka D, Martinez AJ, Radiotherapy or non-functional pituitary adenoma: analysis of long-term tumour control, *J Neurosurg*, 1998;89:933–8.
- Losa M, Valle M, Mortini P, et al., Gamma knife radio-surgery for residual non-functioning pituitary adenomas after surgical de-bulking, *J Neurosurg*, 2004;100:438–44.