

Psychophysical Exams as Early Indicators of Diabetic Retinopathy

Nicola Pescosolido, MD¹ and Giuseppe Buomprisco, MD²

1. Professor, Department of Cardiovascular, Respiratory, Nephrologic, Anesthesiologic and Geriatric Sciences;

2. Resident Physician (Intern), University "Sapienza" of Rome, Faculty of Medicine and Dentistry, Department of Sense Organs, Rome, Italy

Abstract

Retinopathy is a serious and common complication of diabetes that represents the leading cause of blindness, among people of working age, in developed countries. It is estimated that the number of people with diabetic retinopathy (DR) will increase from 126.6 million in 2011 to 191 million by 2030. The visual function that seems to be affected first in the course of DR is probably the contrast sensitivity; in addition, being mainly a macular function, the perception of color is also compromised. Moreover, the duration of the disease, the levels of glycated hemoglobin (HbA_{1c}) and the presence of cystoid macular edema are strongly associated with the impairment of fixation stability in patients with diabetes with clinically significant macular edema, suggesting the possible diagnostic role of microperimetry. The test of contrast sensitivity and the microperimetry and the chromatic sensitivity tests have proved to be useful, safe, reproducible, and inexpensive tools to diagnose the disease early.

Keywords

Diabetic retinopathy, contrast sensitivity, chromatic sensitivity, microperimetry

Disclosure: The authors have no conflicts of interest to declare.

Received: April 22, 2013 **Accepted:** May 18, 2013 **Citation:** *US Endocrinology*, 2014;10(1):30–4

Correspondence: Nicola Pescosolido, MD, University "Sapienza" of Rome, Faculty of Medicine and Dentistry, Department of Cardiovascular, Respiratory, Nephrologic, Anesthesiologic and Geriatric Sciences, Viale del Policlinico 155, 00161, Rome, Italy. E: pescosol@tiscali.it; nicola.pescosolido@uniroma1.it

Diabetes is a metabolic disease consequent to a decrease of insulin activity, which may be due to a reduced availability of this hormone (type 1 diabetes or insulin-dependent diabetes [IDD]), to an impediment to its normal action or to combination of these two factors (type 2 diabetes or non-insulin-dependent diabetes [NIDDM]).

Hyperglycemia is the main characteristic of diabetes. With time, it can lead to vascular and nervous alterations: macro-angiopathy (a severe and early atherosclerosis) and micro-angiopathy (alterations of small arteries that affect the retina particularly, the kidney and the nervous tissue) are the most important ones.

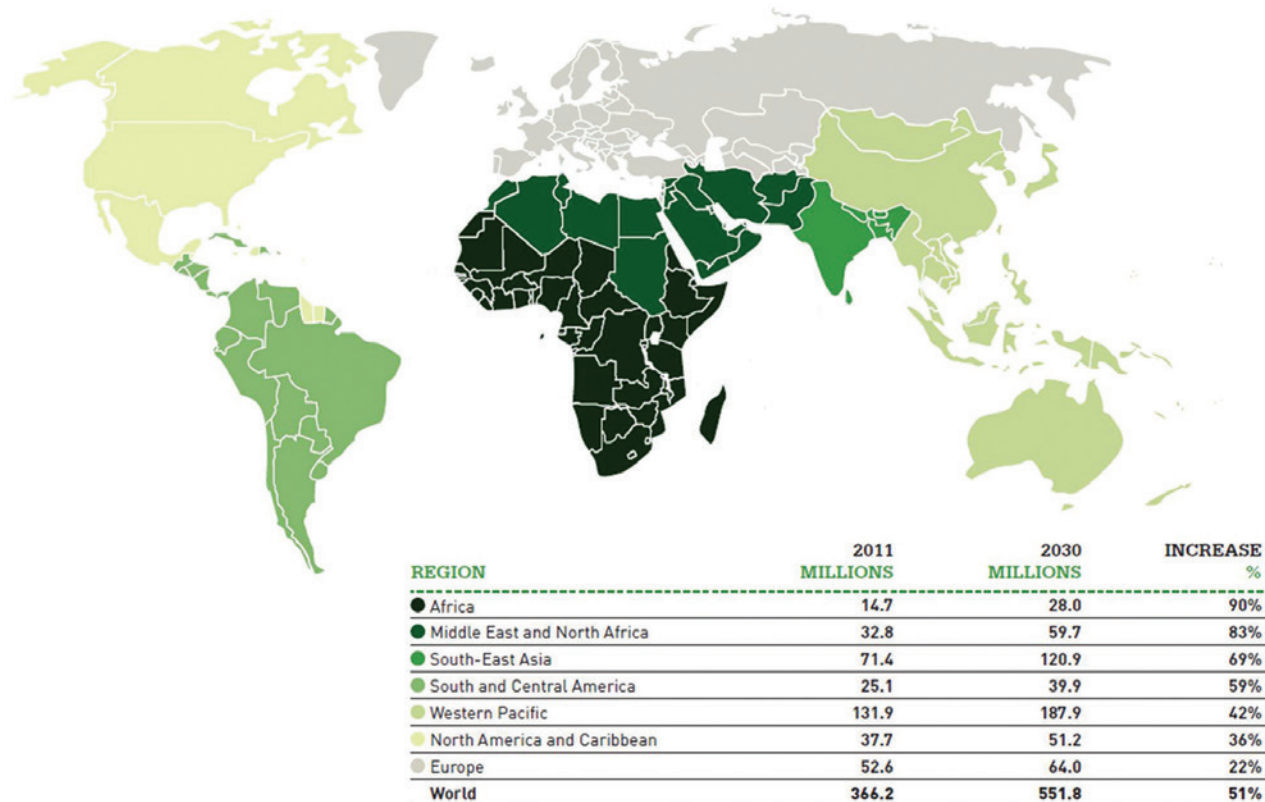
Diabetic retinopathy (DR) is a serious and frequent complication of diabetes, resulting from damage to the retinal microvasculature. Several factors contribute to the development of DR, the main one is that chronic hyperglycemia causes an overproduction of superoxide anion and reactive oxygen species (ROS) and, consequently, it causes the depletion of antioxidant systems. This would lead to the activation of the four main pathways involved in the development of DR: the polyol pathway, the path of hexosamine, the way of diacylglycerol-PKC (protein kinase C) and the way of advanced glycation end-products (AGEs). Hyperglycemia is the initial cause of tissue damage in terms of diabetes. Retinal cells involved in DR are vascular cells – both neuronal and glial. In neurons there is a greater uptake of glucose through the glucose transporter 1 (GLUT1) and sodium-dependent glucose

co-transporter (SGLT) channels. The sum of the changes to these cell populations then results in different degrees of retinopathy.

The initial form of DR, known as 'non-proliferative' (NPDR), is characterized by aneurysms, i.e. the 'breaking' of the thin capillaries that nourish the retina, causing retinal hemorrhages. The advanced form of DR is known as 'proliferative' (PDR), where the formation of capillaries occurs in a totally anarchic way (neovascularization), and the rupture of those form scars, which can lead to a retinal detachment. Unfortunately, eye symptoms of DR occur when the disease is in an advanced stage and has already caused irreversible damage. They are represented by a slow and gradual diminishing of visual acuity associated with a distortion of the images (metamorphopsia) or by a sudden loss of vision in an eye for an extensive hemorrhage or occlusion of a large vessel.

Currently, the diagnosis of DR requires an eye examination with a careful fundus examination and photography with a non-mydriatic fundus camera that documents the current state of the retina allowing a better follow up. Sometimes an optical coherence tomography (OCT) examination (macular edema) or a fluorescein angiography (diagnostic classification and planning of a laser treatment) are required. Despite the fact that visual impairment due to DR is often late and occurs when the anatomical damage is already irreversible, several studies have shown the sensitivity of psychophysical methods to identify signs of the disease already in the preclinical phase.

Figure 1: Trends of the Increase in People with Diabetes by 2030 Divided by Macro-regions



Source: IDF Diabetes Atlas.¹

Epidemiological Notes

Retinopathy occurs in about 85 % of patients with diabetes and, over time, can lead, in a significant percentage of cases, to the complete loss of vision, representing the most common cause of blindness among working-age people in the developed world (data from the International Diabetes Federation).¹

Many risk factors can influence the incidence and prevalence of DR. It is well-established that both the risk of developing a DR and a diabetic macular edema (DME) increase with the duration of diabetes. Other co-factors are hypertension, hyperglycemia, dyslipidemia, pregnancy, puberty, cigarette smoking, cataract surgery, obesity, and poor glycemic control.²

The largest number of epidemiological data regarding this disease derives from large studies such as the Wisconsin Epidemiologic Study of Diabetic Retinopathy (WESDR), the Diabetes Control and Complications Trial (DCCT), the UK Prospective Diabetes Study (UKPDS) and the Early Treatment Diabetic Retinopathy Study (ETDRS) even if they have been very heterogeneous in terms of subject selection and inclusion criteria such as age, ethnicity, comorbidities, and DR stage.³

Currently, worldwide there are about 366 million people with diabetes and this number is expected to increase due to the aging of the world population, urbanisation, and obesity (see *Figure 1*). A recent systematic review of 35 population-based studies showed that the prevalence of

Figure 2: Pelli-Robson Contrast Sensitivity Chart



Figure 3: Curve of Contrast Sensitivity

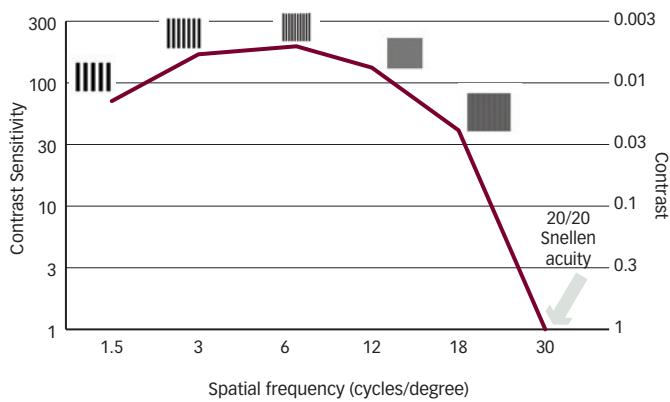
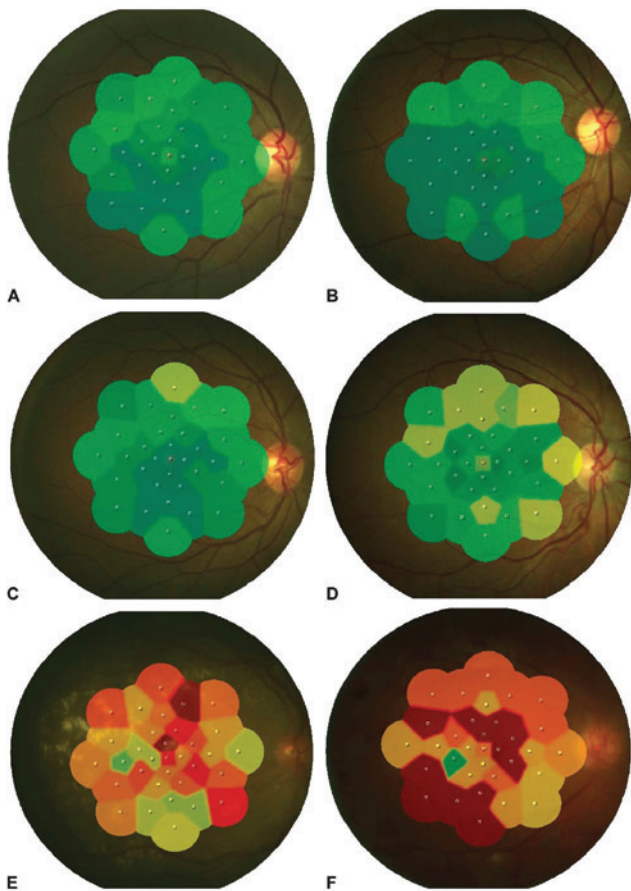


Figure 4: Microperimetry of Healthy Subjects and Subjects with Varying Degrees of Diabetic Retinopathy



A = healthy subjects; B = subjects with diabetes but no retinopathy; C = subjects with mild retinopathy; D = subjects with moderate retinopathy; E = subjects with severe retinopathy; F = subjects with proliferative retinopathy.

various forms of DR in individuals with diabetes is 34.6 % for NPDR, 7.0 % for PDR, 6.8 % for DME and 10.2 % for vision-threatening DR (VTDR).⁴

It is estimated that the number of people with DR will increase from 126.6 million in 2011 to 191 million by 2030 and the number of people

with VTDR will increase from 37.3 to 56.3 million. The National Health and Nutrition Examination Survey (NHANES) study (2005–2008) showed that about the 28.5 % of people with diabetes in the US have some degree of DR, 4.4 % have VTDR⁵ and similar data are deduced in other industrialized countries. In China, it is estimated that today 92.4 million adults have diabetes and that 43 % of them have retinopathy (6.3 % have VTDR).⁶ The WESDR (1984) made the major contribution to research data on the prevalence of retinopathy in the US. The main results were that the overall incidence of DR in a 10-year interval (from 1980/1982 to 1990/1992) was about 74 %, and among those with DR at baseline, 64 % developed some severe form of retinopathy and 17 % underwent the proliferating type.⁷ The incidence was higher in patients with a long history of diabetes and in those who started insulin therapy late. In a 25-year follow-up group with IDD, almost all patients (97 %) developed DR, 42 % progressed to PDR and 29 % developed macular edema with an annual incidence rate of 2.3 %, 2.1 %, 2.3 %, and 0.9 % in the first, second, third, and fourth term follow up, respectively.^{8,9}

Recently,¹⁰ the impact of DR on the quality of life has been evaluated using a questionnaire, the EQ-5D MAUI, which refers to five dimensions (indicators of physical and mental health): mobility, self-care, daily activities, pain/discomfort and anxiety/depression. The study involved 577 people, most of them were males with NIDD. Patients with retinopathy had consistently lower scores on the EQ-5D test than those who had no signs of retinal impairment. Therefore, visual impairment impacted negatively on the quality of life, especially when combined with other complications of diabetes (nephropathy, neuropathy, heart disease, etc.)

The Psychophysical Evaluation

Several psychophysical tests, such as examination of contrast sensitivity, microperimetry and the tests of color perception, have been successfully used in the evaluation of the visual function of patients with DR.

Contrast Sensitivity Tests

The visual function that seems to be affected first by DR is contrast sensitivity. It is defined as a measure of the amount of contrast between light and dark (monochrome or color) required to detect or recognize a unique visual target.¹¹ Most of the visual tasks that people encounter daily require the detection of objects with low contrast. This test, therefore, correlates better than visual acuity (examined with traditional optotypes) to the real visual function.^{12,13} Furthermore it has the advantage of being easy and quick to perform, inexpensive and relatively reproducible.¹⁴

The tests of visual acuity are still valid for the evaluation of refractive defects while it is now clear that many eye diseases, including glaucoma and, indeed, DR, do not affect the ability to discriminate the details (especially in the early stages), but rather other characteristics of visual function. The instruments used to determine it are differentiated by the type of object presented, which can be of two types: a sinusoidal pattern or letters (or characters). A simple example of contrast sensitivity examination is the Pelli-Robson chart (see Figure 2).

Contrast sensitivity is presented as a curve (see Figure 3), which plots the lowest contrast level a patient can detect a specific size target. The x-axis of the curve is for spatial frequency; the y-axis is for contrast sensitivity. Low spatial frequencies are large gratings and high spatial frequencies

are thin gratings. Contrast sensitivity is the inverse of contrast level. The higher the contrast sensitivity, the lower the contrast level at which the patient can detect a target. In normal subjects, the threshold of maximum sensitivity is located towards 3.5 cycles/degree ($C/^\circ$). Furthermore, in low light conditions, the threshold tends to increase, while in conditions of high illumination it tends to lower. Contrast sensitivity can be measured at various spatial frequencies. The examination with contrast variables for different spatial frequencies provides a more complete assessment of the discriminative ability of the human eye.

It is also known as the contrast affects other visual characteristics, such as the perception of colors, and, especially, that it seems to be reduced with the decrease of the apparent velocity of an object. Although both the discrimination of colors and the contrast sensitivity reflect the macular function, their exact physiologic relationship is not yet fully understood.

Trick et al.¹⁵ compared the capacity for these two parameters to identifying the early visual dysfunction in patients with diabetes. They found that 37.8 % of subjects without retinopathy had abnormalities in both tests. That rate rises to 60 % in terms of people with retinopathy. Contrast sensitivity is most frequently abnormal then color discrimination (100 hue test) and rarely individual's deficit of contrast sensitivity and color vision is simultaneous.

Brinchmann-Hansen et al.¹⁶ also found that contrast sensitivity is more closely related to the degree of retinopathy compared with color vision. Misra et al.¹³ found a statistically significant relationship between contrast sensitivity and visual acuity (expressed in LogMAR) and between it and blood levels of glycated hemoglobin (HbA_{1c}). This test on patients with diabetes was altered even when the OCT, the fundus photography, and the visual acuity were absolutely in the norm.¹⁷ Significant loss of contrast sensitivity was observed in patients with IDD who had no evidence of retinopathy compared with controls without diabetes¹⁸⁻²¹ particularly at medium-high spatial frequencies. This is probably due to structural and functional changes in foveal and parafoveal regions caused by different mechanisms, such as dilation of the capillaries (with their possible obliteration and tortuosity) and relative retinal thickening.²² Loukovaara and collaborators,²³ on the contrary, evaluating retinal thickness in women with gestational diabetes and relating it to the contrast sensitivity, showed an increase in retinal thickness and a reduction of sensitivity. Even adolescents, with a relatively short history of IDD, already showed the first signs of a deficit in contrast sensitivity.²⁴

That examination was also used for the evaluation of vision after a pan-retinal laser treatment that often allows to stop, at least, the progression of visual impairment. After the laser treatment, both visual acuity and contrast sensitivity appeared better when comparing with untreated eyes.²⁵ In subsequent work, the stabilization of visual acuity after treatment seemed to be accompanied by an improvement in contrast sensitivity.²⁶

Perimetry and Microperimetry

During normal visual activity, the eye never remains completely still, but while setting a target, it makes small involuntary and targeted movements. The removal of these movements would cause the disappearance of our perception of a stationary target. However, the excessive instability reduces the spatial resolution and can interfere heavily with the visual performance

in everyday tasks, such as reading. All ocular pathologies that affect the central vision alter, more or less extensively, the fixation, one of the most important features for an optimal visual function. Like all maculopathies, DR also affect this capacity (see *Figure 4*).

Al Shafae et al.²⁷ demonstrated a significant loss of macular function on the eyes of patients with pre-diabetes, supporting the hypothesis that neurodegeneration precedes microangiopathy. The Micro-Perimeter perimeter (MP-1) (Nidek Technologies, Padova, Italy) has proved a useful tool to quantify retinal sensitivity in patients with DR allowing the detection of the early loss of retinal sensitivity in patients with diabetes even without clinical evidence of retinopathy.²⁸ Dunbar et al.²⁹ found no significant difference between the scanning laser ophthalmoscope (SLO) and the MP-1 comparing them between 16 control subjects and 21 patients with diabetic maculopathy. Patients with severe PDR, moreover, showed a strongly reduced retinal sensitivity than those with lower stages of DR.³⁰ In particular, the retinal areas affected by exudative phenomena had greater alterations.³¹ The position and the stability of fixation, in patients with diabetic macular edema, seems to be independent from the characteristics of edema, but subfoveal hard exudates have a particularly negative effect on these parameters.³² Visual acuity, retinal sensitivity, central foveal thickness, duration of symptoms, blood levels of HbA_{1c} , and the presence of cystoid macular edema were strongly associated with the impairment of fixation in patients with NIDD and vision-threatening macular edema.³³ In addition, less-sophisticated perimetric techniques such as the white-on-white perimetry^{34,35} and frequency-doubling technology (FDT)³⁶ have been used with success and with similar results.

Color Sensitivity Tests

Being a predominantly macular function, color perception may be compromised by any degenerative process that affects the retina.³⁷ The underlying mechanism is still largely unknown and may refer to a metabolic imbalance of the retina rather than a microvascular impairment.³⁸ Several tests are available to assess the color vision but the results can be influenced by the presence of lens opacity or by genetic defects of color discrimination.^{39,40} One of the most widely used tests, together with Ishihara's plates, is Farnsworth-Munsell's 100 hue test.⁴¹ In a study of young patients with IDD,⁴² this test has proved to be relatively more sensitive and specific in detecting visual dysfunction compared with the electroretinogram. Most of the results confirm that a significant deterioration of color vision (mainly evaluated by the test of Farnsworth-Munsell) occurs in patients with diabetes without retinopathy compared with non-diabetic controls.⁴³ More specifically, the sensitivity to yellow-blue frequencies seems to be more affected.^{44,45} Some authors believe that this alteration is due to a loss of yellow-blue sensitive cones (S-cones),^{46,47} while Knowles et al.⁴⁸ and Tregear et al.⁴⁹ suggested that at the basis of this defect of color perception is essentially the browning of the lens. The color perception, in fact, improved in subjects operated of phacoemulsification and implantation of intra-ocular lens (IOL) with blue light filter.⁵⁰

In 1998, Mahon and colleagues⁵¹ concluded that untreated eyes with proliferative retinopathy had deficits in the discrimination of hue more pronounced than light sensitivity. The laser treatment (pan-retinal photocoagulation [PRP]), according to the authors, seemed to produce a

paradoxical normalization of the perception of light (saturation) but a still impaired chromatic sensitivity.

Ong et al.⁵² argued that the assessment of color perception is even more sensitive and specific of fundus photography in the detection of DR with visual impairment. The same authors, in a previous work,⁵³ concluded that this test, for the screening of DR, is more sensitive for the assessment of visual acuity.

Conclusions

It is evident that diabetes deeply involves the psychophysical aspects of visual function. Color perception and contrast sensitivity,

in particular, seem to be the functions that are mainly compromised, even before the visual acuity. They are impaired before structural retinal abnormalities can be detected through ophthalmoscopy or fluorangiography.

Moreover those exams are inexpensive, reproducible, non-invasive and affordable for any eye clinic. We need to escalate the use of these diagnostic methods in everyday clinical practice to improve our approach to patient care and, above all, to achieve a secondary prevention (screening) itself. Microperimetry, moreover, is not only useful for visual rehabilitation but, as we have seen, in the early diagnosis of various retinal diseases too, including DR. ■

1. IDF Diabetes Atlas, 5th ed, Brussels, Belgium: International Diabetes Federation, 2011.
2. Cheung N, Mitchell P, Wong TY, Diabetic retinopathy, *Lancet*, 2010;376:124–36
3. Petrella RJ, Blouin J, Davies B, Barbeau M, Prevalence, Demographics, and Treatment Characteristics of Visual Impairment due to Diabetic Macular Edema in a Representative Canadian Cohort, *J Ophthalmol*, 2012;2012:159–67.
4. Yau JW, Rogers SL, Kawasaki R, et al., Global prevalence and major risk factors of diabetic retinopathy, *Diabetes Care*, 2012;35:556–64
5. Zhang X, Saaddine JB, Chou CF, et al., Prevalence of diabetic retinopathy in the United States, 2005–2008, *JAMA*, 2010;304:649–56.
6. Wang FH, Liang YB, Zhang F, et al., Prevalence of diabetic retinopathy in rural China. The Handan Eye Study, *Ophthalmology*, 2009;116:461–7.
7. Klein R, Knudtson MD, Lee KE, et al., The Wisconsin epidemiologic study of diabetic retinopathy XXIII: The twenty-five-year incidence of macular edema in persons with type 1 diabetes, *Ophthalmology*, 2009;116:497–503.
8. Klein R, Epidemiology of diabetic retinopathy. In: Duh E (editor), *Diabetic Retinopathy*, Totowa: Humana Press, 2008.
9. Wong TY, Mwamburi M, Klein R, et al., Rates of progression in diabetic retinopathy during different time periods: A systematic review and meta-analysis, *Diabetes Care*, 2009;32:2307–13.
10. Fenwick E, Rees G, Pesudovs K, et al., Social and emotional impact of diabetic retinopathy: A review, *Clin Experiment Ophthalmol*, 2012;40:27–38.
11. Di Leo MAS, Caputo S, Falsini B, et al., Nonselective loss of contrast sensitivity in visual system testing in early type 1 diabetes, *Diabetes Care*, 1992;15:620–25.
12. Sokol S, Moskowitz A, Skarf B, et al., Contrast sensitivity in diabetics with and without background retinopathy, *Arch Ophthalmol*, 1985;103:51–4.
13. Misra S, Saxena S, Kishore P, et al., Association of contrast sensitivity with LogMAR visual acuity and glycosylated hemoglobin in non-insulin dependent diabetes mellitus, *J Ocul Biol Dis Inform*, 2010;3:60–3.
14. Della Salla S, Bertoni G, Somazzi L, Impaired contrast sensitivity in diabetic patients with and without retinopathy: a new technique for rapid assessment, *Br J Ophthalmol*, 1985;69:136–42.
15. Trick GL, Burde RM, Gordon MO, et al., The relationship between hue discrimination and contrast sensitivity deficits in patients with diabetes mellitus, *Ophthalmology*, 1988;95:693–8.
16. Brinchmann-Hansen O, Bangstad HJ, Hultgren S, et al., Psychophysical visual function, retinopathy and glycaemic control in insulin-dependent diabetics with normal visual acuity, *Acta Ophthalmol*, 1993;71:230–37.
17. Katz G, Levkovitch-Verbin H, Treister G, et al., Mesopic foveal contrast sensitivity is impaired in diabetic patients without retinopathy, *Graefes Arch Clin Exp Ophthalmol*, 2010;248:1699–1703.
18. Ghafoor IM, Foulds WS, Allan D, McClure E, Contrast sensitivity in diabetic subjects with and without retinopathy, *Br J Ophthalmol*, 1982;66:492–5.
19. Liska V, Dostálek M, Are contrast sensitivity functions impaired in insulin dependent diabetics without diabetic retinopathy? *Acta Medica (Hradec Kralove)*, 1999;42:133–8.
20. Suckha AY, Rubin A, High, medium and low contrast visual acuities in diabetic retinal disease, *Optom Vis Sci*, 2009;86:1086–95.
21. Stavrou EP, Wood JM, Letter contrast sensitivity changes in early diabetic retinopathy, *Clin Exp Optom*, 2003;86:152–6.
22. Krasny J, Andel M, Brunnerova R, et al., The contrast sensitivity test in early detection of ocular changes in the relation to the type I diabetes mellitus compensation in children, teenagers, and young adults, *Recent Pat Inflamm Allergy Drug Discov*, 2007;1:232–6.
23. Loukovaara S, Harju M, Kaaja RJ, Immonen IJ, Topographic change in the central macula coupled with contrast sensitivity loss in diabetic pregnancy, *Graefes Arch Clin Exp Ophthalmol*, 2003;24:607–14.
24. Georgakopoulos CD, Eliopoulou MI, Exarchou AM, et al., Decreased contrast sensitivity in children and adolescents with type 1 diabetes mellitus, *J Pediatr Ophthalmol Strabismus*, 2011;48:92–7.
25. Lövestam-Adrian M, Svendenius N, Agardh E, Contrast sensitivity and visual recovery time in diabetic patients treated with panretinal photocoagulation, *Acta Ophthalmol Scand*, 2000;78:672–6.
26. Talwar D, Sharma N, Pai A, et al., Contrast sensitivity following focal laser photocoagulation in clinically significant macular oedema due to diabetic retinopathy, *Clin Experiment Ophthalmol*, 2001;29:17–21.
27. Al Shafae M, Shenoy R, Bialasiewicz AA, et al., Macular function in prediabetic and diabetic Omani adults: a microperimetric evaluation, *Eur J Ophthalmol*, 2011;21:771–6.
28. Verma A, Rani PK, Raman R, et al., Is neuronal dysfunction an early sign of diabetic retinopathy? Microperimetry and spectral domain optical coherence tomography (SD-OCT) study in individuals with diabetes, but no diabetic retinopathy, *Eye (Lond)*, 2009;23:1824–30.
29. Dunbar HMP, Crossland MD, Rubin GS, Fixation Stability: A Comparison between the Nidek MP-1 and the Rodenstock Scanning Laser Ophthalmoscope in persons with and without diabetic maculopathy, *Invest Ophthalmol Vis Sci*, 2010;51:4346–50.
30. Nittala MG, Gella L, Raman R, Sharma T, Measuring retinal sensitivity with the microperimeter in patients with diabetes, *Retina*, 2012;32:1302–9.
31. Soliman W, Hasler P, Sander B, Larsen M, Local retinal sensitivity in relation to specific retinopathy lesions in diabetic macular oedema, *Acta Ophthalmol*, 2012;90:248–53.
32. Vujosevic S, Pilotto E, Bottega E, et al., Retinal fixation impairment in diabetic macular edema, *Retina*, 2008;28:1443–50.
33. Carpineto P, Ciancaglini M, Di Antonio L, et al., Fundus microperimetry patterns of fixation in type 2 diabetic patients with diffuse macular edema, *Retina*, 2007;27:21–9.
34. Parravano M, Oddone F, Mineo D, et al., The role of Humphrey Matrix testing in the early diagnosis of retinopathy in type 1 diabetes, *Br J Ophthalmol*, 2008;92:1656–60.
35. Nitta K, Saito Y, Kobayashi A, Sugiyama K, Influence of clinical factors on blue-on-yellow perimetry for diabetic patients without retinopathy: comparison with white-on-white perimetry, *Retina*, 2006;26:797–802.
36. Jackson GR, Scott IU, Quillen DA, et al., Inner retinal visual dysfunction is a sensitive marker of non-proliferative diabetic retinopathy, *Br J Ophthalmol*, 2012;96:699–703.
37. Kinnear PR, Aspinall PA, Lakowski R, The diabetic eye and colour vision, *Trans Ophthalmol Soc UK*, 1972;92:69–78.
38. Hardy KJ, Lipton J, Scase MO, et al., Detection of colour vision abnormalities in uncomplicated type 1 diabetic patients with angiographically normal retinas, *Br J Ophthalmol*, 1992;76:461–4.
39. Roy MS, Gunkel RD, Podgor MJ, Color vision defects in early diabetic retinopathy, *Arch Ophthalmol*, 1986;104:225–8.
40. Roy MS, McCulloch C, Hanna AK, Mortimer C, Colour vision in long-standing diabetes mellitus, *Br J Ophthalmol*, 1984;68:215–17.
41. Farnsworth D (ed), *The Farnsworth-Munsell 100 Hue Test Manual*, Baltimore, MD: Munsell Color Co., 1957.
42. Hardy KJ, Fisher C, Heath P, et al., Comparison of colour discrimination and electroretinography in evaluation of visual pathway dysfunction in retinopathic IDDM patients, *Br J Ophthalmol*, 1995;79:35–7.
43. Bresnick GH, Condit RS, Palta M, et al., Association of hue discrimination loss and diabetic retinopathy, *Arch Ophthalmol*, 1985;103:1317–24.
44. Lakowski R, Aspinall PA, Kinnear PR, Association between colour vision losses and diabetes mellitus, *Ophthalmol Res*, 1972;4:145–59.
45. Lombrail P, Gervais P, Cathelineau G, Prediction of diabetic retinopathy from color vision data, *Diabetes Care*, 1983;6:621–2.
46. Terasaki H, Hirose H, Miyake Y, S-Cone pathway sensitivity in diabetes measured with threshold versus intensity curves on flashed backgrounds, *Invest Ophthalmol Vis Sci*, 1996;37:680–84.
47. Yamamoto S, Kamiyama M, Nitta K, et al., Selective reduction of the S cone electroretinogram in diabetes, *Br J Ophthalmol*, 1996;80:973–5.
48. Knowles PJ, Tregear SJ, Ripley LG, Casswell AG, Colour vision in diabetic and normal pseudophakia is worse than expected, *Eye (Lond)*, 1996;10:113–16.
49. Tregear SJ, Knowles PJ, Ripley LG, Casswell AG, Chromatic-contrast threshold impairment in diabetes, *Eye*, 1997;11:537–46.
50. Rodríguez-Galietero A, Montés-Micó R, Muñoz G, Albarrán-Diego C, Blue-light filtering intraocular lens in patients with diabetes: contrast sensitivity and chromatic discrimination, *J Cataract Refract Surg*, 2005;31:2088–92.
51. Mahon LE, Vingrys AJ, Fleiszig SM, Evidence for non-selective colour channel involvement in diabetic eyes especially after laser treatment, *Clin Exp Optom*, 1998;81:272–9.
52. Ong GL, Ripley LG, Newsom RSB, et al., Screening for sight-threatening diabetic retinopathy: comparison of fundus photography with automated color contrast threshold test, *Am J Ophthalmol*, 2004;137:445–52.
53. Ong GL, Ripley GL, Newsom RSB, Casswell AG, Assessment of colour vision as a screening test for sight threatening diabetic retinopathy before loss of vision, *Br J Ophthalmol*, 2003;87:747–52.